

Effect of extraction of first four premolars on smile aesthetics

Farhana Ghaffar and Mubassar Fida

Section of Dentistry, Department of Surgery, The Aga Khan University Hospital, Karachi, Pakistan

Correspondence to: Dr Mubassar Fida, Orthodontics, Section of Dentistry, Department of Surgery, The Aga Khan University Hospital, Stadium Road, Karachi 74800, Pakistan. E-mail: mubassar.fida@aku.edu

SUMMARY The objective of the present study was to assess smile aesthetics after orthodontic treatment in subjects with and without the extraction of four first premolars. Post-treatment coloured frontal photographs (4 × 6 inches) of 60 Pakistani subjects, 21 males and 39 females, aged between 15 and 30 years were assessed by one examiner. For 50 per cent ($n = 30$) of the patients, treatment included the extraction of four first premolars, whereas the other half were treated without extractions. Smile aesthetics were evaluated by a panel of 10 laypersons, five males and five females, aged between 20 and 30 years. Smile aesthetic parameters were measured using seven variables, and the ratios were calculated. An independent sample *t*-test was used to assess smile aesthetics.

All seven variables namely smile width, smile height, visible dentition width, maxillary intercanine width, visible maxillary first molars, visible mandibular teeth, visible maxillary gingival margin, and the ratios between the above mentioned variables showed no detrimental effects following extraction of four first premolars on smile aesthetics.

Introduction

Aesthetics in orthodontic treatment have always been associated with profile enhancement (Sabri, 2005). Facial beauty and harmony were the primary treatment objectives of Angle (James, 1998). However, Angle's classification of malocclusion and cephalometric analyses focused more on the profile and less on the frontal view. The orthodontic literature to date has more studies on skeletal than on soft tissue relationships and smile aesthetics (Sabri, 2005).

An attractive balanced smile is a prime objective of modern orthodontic therapy (Roden-Johnson *et al.*, 2005). The beauty of the smile lies in the orthodontists' ability to recognize the positive factors in smile aesthetics enhancement and to plan treatment accordingly (Sarver and Ackerman, 2003a,b). This topic has gained importance for clinicians as orthodontic patients evaluate the outcome of their treatment not only through occlusal harmony but also through their smiles and the enhancement in facial appearance at the end of treatment (İşiksal *et al.*, 2006).

Extensive studies have resulted in the establishment of norms that orthodontists use as guidelines to evaluate facial form and to direct therapy. Research supporting these established norms has been directed to the lateral view of the face and most of the knowledge has been derived from it (Roden-Johnson *et al.*, 2005). However, Mackley (1993) demonstrated that the profile is not a reliable predictor of the appearance of a person's smile.

Smile and facial attractiveness are strongly correlated. Smile aesthetics are influenced by features such as the amount of gingival display, the presence of a smile arc, and

the shade of the teeth. A smile with minimal gingival display has been considered more aesthetically pleasing than one with excessive gingival display (Hulsey, 1970; Rigsbee *et al.*, 1988; Kokich *et al.*, 1999). In an attractive smile, the upper lip elevates to reveal approximately 10 mm of the maxillary incisors, the mouth increases to 130 per cent of its original width, and the lips are separated approximately 12 mm (Peck and Peck, 1995). The location of the gingival smile line is also dependent on the subject's gender. On average, the smile line in females is 1.5 mm higher than in males (Sarver, 2001), with a smile exhibiting the upper lip at the height of the gingival margin of the maxillary central incisors being more attractive (Hulsey, 1970). A smile showing the curvature of the maxillary incisal edges (smile arc) that parallels the curvature of the lower lip has been reported to be more aesthetic than one with a flat maxillary incisal edge (Hulsey, 1970; Sarver, 2001; Sarver and Ackerman, 2003a,b). Furthermore, coincidence of the maxillary midlines with the facial midline has been found to be important (Tjan *et al.*, 1984), as has a light shade of the teeth (Dunn *et al.*, 1996).

Another important smile feature is the presence or absence of buccal corridors. Frush and Fisher (1958) defined a buccal corridor as the space between the facial surfaces of the posterior teeth and the corners of the lips during smiling. A broad smile with minimal buccal corridors is considered to be more attractive than a narrow smile with large buccal corridors when judged by laypersons (Moore *et al.*, 2005). The presence or absence of buccal corridors during smiling shows no significant difference in smile scores among

dentists, orthodontists, and laypersons (Roden-Johnson *et al.*, 2005). Ker *et al.* (2008), in a computer-based survey on aesthetics and smile characteristics from the layperson's perspective, concluded that raters preferred a broader smile. Smiles displaying the maxillary first permanent molars are considered to be more aesthetic (Yoon *et al.*, 1992; Dong *et al.*, 1999).

Smile aesthetics vary for different subjects according to their age, gender, and race. Females tend to present a softer appearance than males (Frush and Fisher, 1958) and have greater facial animation than males during smiling (Rigsbee *et al.*, 1988). With age, the upper lip tends to conceal more of the maxillary incisors and a concomitant greater degree of mandibular incisor display (Zachrisson, 1998, 2007).

Some investigators have noted a difference in how laypeople and dentists evaluate and rate the smile (Brisman, 1980; Kokich *et al.*, 1999). However, according to Wylie (1955), the layman's opinion of the human profile is every bit as good as the orthodontists and perhaps even better since it is not conditioned by orthodontic propaganda.

Recent criticism concerning the detrimental effects of premolar extractions on smile aesthetics has added another dimension to the debate concerning extraction versus non-extraction treatment (Kim and Gianelly, 2003). It is thought that extraction leads to constricted dental arches, which in turn result in increased buccal corridors, thus making the smile less aesthetic (Spahl and Witzig, 1987). Studies on the detrimental effects of premolar extraction are still limited. The aim of this investigation was to assess smile aesthetics after orthodontic treatment in subjects with and without extraction of the four first premolars.

Materials and methods

Data for this study were obtained from post-treatment frontal photographs of Pakistani subjects at the Orthodontic Clinic, Section of Dentistry, Aga Khan University Hospital, Karachi, Pakistan, treated consecutively over a period of 5 years (2002–2007) with fixed mechanotherapy. The patients were aged between 15 and 30 years. Exclusion criteria were no previous orthodontic treatment, congenitally missing teeth other than third molars, or craniofacial anomalies and syndromes.

Following assessment of the post-treatment frontal photographs by one author (FG), two groups of 30 patients were formed; an extraction group (10 males and 20 females) in whom the four first premolars were extracted and a non-extraction group (11 males and 19 females). The photographs of the patients had been taken with a single Nikon-5700 camera (maximum resolution 2560 × 1920, pixels 8 MP/cm, digital zoom; Nikon Corporation, Tokyo, Japan). Coloured glossy printed photographs (4 × 6 inches) were produced for each exposure. The selected photographs were then covered with black construction paper leaving only a

proportionate rectangular area around the mouth (Figure 1). Smile aesthetics were evaluated by a panel of 10 laypersons, five males and five females, aged between 20 and 30 years; the only exclusion criteria was a professional background in any aspect of dentistry. They were asked to score each photograph using the following scale: 1 = poor, 2 = fair, 3 = good, 4 = very good, and 5 = excellent (Johnson and Smith, 1995).

Measurements obtained for each photograph, with landmarks as defined by Philips *et al.* (1984), were carried out by one author (FG; Table 1, Figure 2). Data analysis was undertaken using the Statistical Package for Social Sciences for Windows version 16.0 (SPSS Inc., Chicago, Illinois, USA). The mean and standard deviation of all the measurements for both the extraction and the non-extraction groups were computed. Comparison between both groups was undertaken using an independent sample *t*-test and *P*-value of 0.05 or less was considered to be significant.

As measurements on photographs are not as precise as on cephalometric radiographs, the ratios were calculated for measurements 1–4 (Table 1). To determine measurement error, 10 photographs were randomly selected by same examiner and remeasured after a period of 1 month using a paired sample *t*-test (Table 2).

Results

A total of 60 photographs were assessed by the laypersons and the principal examiner. Table 3 shows the comparison of the smile aesthetic variables between the extraction and non-extraction groups as judged by the principal examiner. There was no statistically significant difference in any smile aesthetic parameters between the two groups.

The distribution related to non-parametric variables such as visible maxillary first molar, visible mandibular teeth, and visible maxillary gingival margin in the extraction and non-extraction groups are shown in Table 4 as judged by the principal examiner. No significant differences were observed between the groups. The mean aesthetic scores of subjects in the extraction and non-extraction groups as judged by laypersons showed no significant difference between the groups.

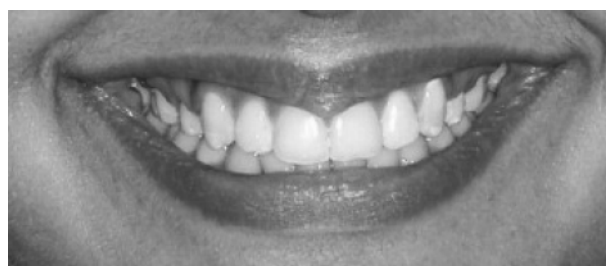

Figure 1 Photograph showing the rectangular area around the mouth.

Table 1 Smile aesthetic variables.

Smile width: the distance between the most medial points of the lips at the angles of the mouth [left (CHL) to right (CHR) cheilion].

Smile height: distance from the most inferior point on the upper lip between the maxillary central incisors to the most superior point on the lower lip on a perpendicular vertical line from the upper point (upper stomion to lower stomion, UST–LST).

Visible dentition width: distance between the most lateral left and right buccal points of the maxillary dentition.

Maxillary intercanine width: distance between the most distal visible points on the canines.

Presence or absence of visible maxillary first molars: Molars were classified as visible if any portion of the tooth could be seen. This variable was coded as absent = 0, present unilateral = 1, or present bilateral = 2.

Presence (= 1) or absence (= 0) of any visible mandibular teeth.

Presence (= 1) or absence (= 0) of any visible maxillary gingival margin.

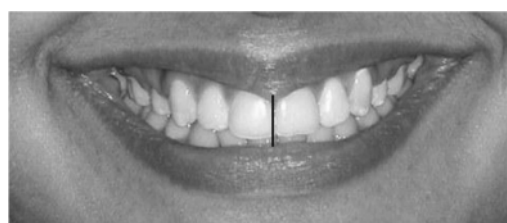
Measurements 1–4 were used to define several ratios:

$$\text{Ratio 1: } \frac{\text{Maxillary intercanine width}}{\text{Smile width}}$$

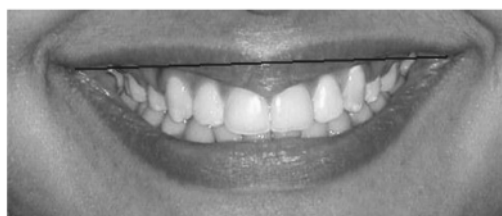$$\text{Ratio 2: } \frac{\text{Smile height}}{\text{Smile width}}$$

$$\text{Ratio 3: } \frac{\text{Visible dentition width}}{\text{Smile width}}$$

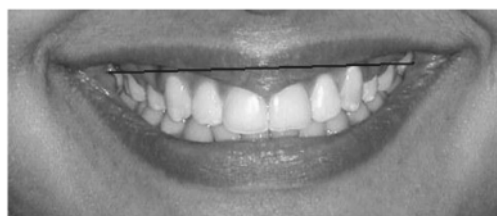$$\text{Ratio 4: } \frac{\text{Maxillary intercanine width}}{\text{Visible dentition width}}$$



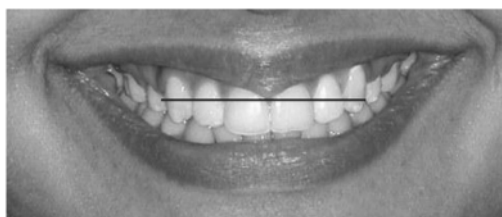Smile height



Smile width



Visible dentition width



Maxillary intercanine width

Figure 2 Smile aesthetic variables.**Table 2** Measurement error for the smile aesthetic variables between the extraction and non-extraction groups using a paired sample *t*-test.

Variables compared between extraction and non-extraction groups	Paired differences		
	Mean	SD	Significance (two-tailed)
Smile width (sw)	0.20	0.42	0.17
Smile height (sh)	–0.20	0.42	0.17
Visible dentition width (vdw)	0.00	0.47	1.00
Maxillary intercanine width (miw)	0.30	0.67	0.19
miw/sw	0.00	0.00	0.73
sh/sw	–0.00	0.01	0.99
vdw/sw	0.00	0.01	0.69

Table 3 Comparison of smile aesthetic variables between the extraction (*n* = 30) and non-extraction (*n* = 30) groups as assessed by the principal examiner.

Variables	Extraction–Non-extraction	Mean	SD	<i>P</i>
Smile width	Extraction	30.63	7.41	0.64
	Non-extraction	29.73	7.53	
Smile height	Extraction	5.7	2.53	0.61
	Non-extraction	5.4	1.99	
Visible dentition width	Extraction	26.30	7.66	0.63
	Non-extraction	25.43	6.21	
Maxillary intercanine width	Extraction	20.80	5.58	0.41
	Non-extraction	19.52	6.36	
Maxillary intercanine width/smile width	Extraction	0.67	0.07	0.92
	Non-extraction	0.66	0.07	
Smile height/smile width	Extraction	0.17	0.06	0.79
	Non-extraction	0.17	0.04	
Visible dentition width/smile width	Extraction	0.84	0.12	0.8
	Non-extraction	0.84	0.06	
Maxillary intercanine width/visible dentition width	Extraction	0.77	0.10	0.52
	Non-extraction	0.79	0.07	

Test of significance: independent sample *t*-test; level of significance, *P* = 0.05.

Table 4 Comparison of non-parametric variables between the extraction and non-extraction groups as assessed by the principal examiner.

Characteristic	Group		P
	Extraction, n = 30	Non-extraction, n = 30	
Visible maxillary first molar			
Absent	21	24	0.5
Unilateral present	3	1	
Bilaterally present	6	5	
Visible mandibular teeth			
Absent	17	15	0.6
Present	13	15	
Visible maxillary gingival margin			
Absent	13	12	0.7
Present	17	18	
Total observations	30	30	

Test of significance: chi-square; level of significance 0.05.

Discussion

Only a few studies (Spahl and Witzig, 1987; Johnson and Smith, 1995; Kim and Gianelly, 2003) have been carried out to assess and compare the effects of premolar extractions on smile aesthetics, and documentation on the adverse effects of extraction treatment is still limited. This study was undertaken to assess smile aesthetics after orthodontic treatment in subjects treated with or without extraction of four first premolars.

The findings showed no significant difference in smile aesthetics when the extraction and non-extraction groups were compared. Buccal corridor spaces have been described by several investigators as undesirable (Lombardi, 1973; Blitz, 1997; Gianelly, 2003; Sarver and Ackerman, 2003a,b). Orthodontists and laypeople rate smiles with small buccal corridors as significantly more attractive than those with large buccal corridors. In fact, orthodontists rate first molar to first molar smiles as more attractive, whereas laypeople prefer second premolar to second premolar smiles (Martin *et al.*, 2007).

Some orthodontists consider that extraction causes an arch width reduction that could lead to a decrease in the buccal corridor ratio and poor smile aesthetics (Spahl and Witzig, 1987). Hulsey (1970) found that the mean rated smile scores of orthodontically treated subjects were significantly lower than those of subjects with normal occlusions. In contrast, Johnson and Smith (1995) and Mackley (1993) concluded that variables related to the buccal corridor or other measurements of the relationship between the width of the dentition and mouth during smiling showed no relationship with smile aesthetics. They determined that smile aesthetics, aesthetic scores, and visible dentition during smiling were the same in both the extraction and the non-extraction groups.

Similarly, a study by Yang *et al.* (2008) that investigated hard and soft tissue factors related to the amount of buccal

corridor area during posed smiling concluded that there was no significant difference in the buccal corridor area ratio between extraction and non-extraction groups. McNamara *et al.* (2008) studied various skeletal, dental, and soft tissue relationships related to the aesthetics of smile and found no significant correlations between smile arc, amount of incisogingival display, size of the buccal corridors, and smile aesthetics in malocclusion patients. The results of the present research are in agreement with those studies; variables such as smile width, smile height, visible dentition width, and maxillary intercanine width showed no significant difference on smile aesthetics between subjects treated with or without four first premolar extractions.

Gianelly (2003) and Kim and Gianelly (2003) on examining the arch width of patients treated with extractions or non-extraction found no differences in arch width between the two treatment protocols and noted that extraction does not produce buccal corridor spaces. According to Luppapornlarp and Johnston (1993), the post-treatment intercanine widths of the maxillary and mandibular arches were again the same in the extraction and non-extraction groups.

Prahl-Andersen *et al.* (1979) and Peck *et al.* (1992a,b) indicated that dentists and laypersons judge facial aesthetics differently as dentists have been trained to observe features that do not seem to influence the general public. In the current study, the smiles evaluated by laypersons did not show any significant difference ($P = 0.8$) between the extraction and non-extraction groups.

It is assumed that a smile displaying the maximum number of teeth is considered to be the most aesthetic. According to Tjan *et al.* (1984), a typical or average smile displays the six maxillary anterior teeth and first or second premolars in young adults. In the present study, the subjects treated with and without extraction of four first premolars displayed an equal number of teeth during smiling. Similarly, in the study of Kim and Gianelly (2003), the number of teeth visible during smiling in both the extraction and non-extraction groups was similar with half of the subjects displaying 10 teeth. The results of the present research showed that in both groups, only a few subjects exhibited the maxillary first molars during smiling. This is in agreement with the study of Tjan *et al.* (1984) who reported that only a small percentage of the population will show the maxillary first molars during smiling. However, Johnson and Smith (1995) and Mackley (1993) emphasized that patients with better aesthetic scores had a significantly greater frequency of visible maxillary first molars.

The most important feature of the smile that affects aesthetics is the amount of maxillary gingival display (Mack, 1991; Peck *et al.*, 1992a,b). There is no evidence that extraction treatment has an effect on this feature. The results of the present study also demonstrated no deleterious effects of four first premolar extractions on the amount of maxillary gingival margin display during smiling.

The findings of the present investigation also showed that there was no difference between smile aesthetics in the extraction and non-extraction groups, thus the decision regarding extraction of the four first premolars in treatment planning should not be solely based on smile aesthetics but factors such as overjet, overbite, crowding, and soft tissue characteristics should be taken into consideration.

Conclusions

1. No significant differences were seen in smile aesthetic parameters of orthodontic patients treated with and without extraction of the four first premolars.
2. The smile aesthetic scores of subjects treated with and without extraction of the four first premolars did not show any statistically significant difference.

References

- Blitz N 1997 Criteria for success in creating beautiful smiles. *Oral Health* 87: 38–42
- Brisman A S 1980 Esthetics: a comparison of dentists' and patients' concepts. *Journal of the American Dental Association* 100: 345–352
- Dong J K, Jin T H, Cho H W, Oh S C 1999 The esthetics of the smile: a review of some recent studies. *International Journal of Prosthodontics* 12: 9–19
- Dunn W J, Murchinson D F, Broome J C 1996 Esthetics: patients' perceptions of dental attractiveness. *Journal of Prosthodontics* 5: 166–171
- Frush J P, Fisher R D 1958 The dynesthetic interpretation of the dentogenic concept. *Journal of Prosthetic Dentistry* 8: 558–568
- Gianelly A A 2003 Arch width after extraction and non-extraction treatment. *American Journal of Orthodontics and Dentofacial Orthopedics* 123: 25–28
- Hulsey C M 1970 An esthetic evaluation of lip-teeth relationships present in the smile. *American Journal of Orthodontics* 57: 132–144
- Işıkşal E, Hazar S, Akyalçın S 2006 Smile esthetics: perception and comparison of treated and untreated smiles. *American Journal of Orthodontics and Dentofacial Orthopedics* 129: 8–16
- James R D 1998 A comparative study of facial profiles in extraction and non-extraction treatment. *American Journal of Orthodontics and Dentofacial Orthopedics* 114: 265–276
- Johnson D K, Smith R J 1995 Smile esthetics after orthodontic treatment with and without extraction of four first premolars. *American Journal of Orthodontics and Dentofacial Orthopedics* 108: 162–167
- Ker A J, Chan R, Fields H W, Beck M, Rosensteel S 2008 Esthetics and smile characteristics from the layperson's perspective: a computer-based survey study. *Journal of the American Dental Association* 139: 1318–1327
- Kim E, Gianelly A A 2003 Extraction vs non-extraction: arch widths and smile esthetics. *Angle Orthodontist* 73: 354–358
- Kokich V O Jr, Kiyak A H, Shapiro P A 1999 Comparing the perception of dentists and lay people to altered dental esthetics. *Journal of Esthetic Dentistry* 11: 311–324
- Lombardi R E 1973 The principles of visual perception and their clinical application to denture esthetics. *Journal of Prosthetic Dentistry* 29: 358–382
- Luppanapornlarp S, Johnston L E Jr. 1993 The effects of premolar extraction: a long term comparison of outcomes in clear-cut extraction and nonextraction Class II patients. *Angle Orthodontist* 63: 257–272
- Mack M R 1991 Vertical dimension: a dynamic concept based on facial form and oropharyngeal function. *Journal of Prosthetic Dentistry* 66: 478–485
- Mackley R J 1993 An evaluation of smiles before and after orthodontic treatment. *Angle Orthodontist* 63: 183–189
- Martin A J, Buschang P H, Boley J C, Taylor R W, McKinney T W 2007 The impact of buccal corridors on smile attractiveness. *European Journal of Orthodontics* 29: 530–537
- McNamara L, McNamara J A Jr, Ackerman M B, Baccetti T 2008 Hard- and soft-tissue contributions to the esthetics of the posed smile in growing patients seeking orthodontic treatment. *American Journal of Orthodontics and Dentofacial Orthopedics* 133: 491–499
- Moore T, Southard K A, Casco J S, Qian F, Southard T E 2005 Buccal corridors and smile esthetics. *American Journal of Orthodontics and Dentofacial Orthopedics* 127: 208–213
- Peck S, Peck L 1995 Selected aspects of the art and science of facial esthetics. *Seminars in Orthodontics* 1: 105–126
- Peck S, Peck L, Kataja M 1992a The gingival smile line. *Angle Orthodontist* 62: 91–100
- Peck S, Peck L, Kataja M 1992b Some vertical lineaments of lip position. *American Journal of Orthodontics and Dentofacial Orthopedics* 101: 519–524
- Philips C, Greer J, Vig P, Matteson S 1984 Photocephalometry: errors of projection and landmark location. *American Journal of Orthodontics* 86: 233–243
- Prahl-Andersen B, Boersma H, Van der Linden F P, Moore A W 1979 Perceptions of dentofacial morphology by laypersons, general dentists, and orthodontists. *Journal of the American Dental Association* 98: 209–212
- Rigsbee O H III, Sperry T P, BeGole E A 1988 The influence of facial animation on smile characteristics. *International Journal of Adult Orthodontics and Orthognathic Surgery* 3: 233–239
- Roden-Johnson D, Gallerano R, English J 2005 The effects of buccal corridor spaces and arch form on smile esthetics. *American Journal of Orthodontics and Dentofacial Orthopedics* 127: 343–350
- Sabri R 2005 The eight components of a balanced smile. *Journal of Clinical Orthodontics* 39: 155–167
- Sarver D 2001 The importance of incisor positioning in the esthetic smile: the smile arc. *American Journal of Orthodontics and Dentofacial Orthopedics* 120: 98–111
- Sarver D M, Ackerman M B 2003a Dynamic smile visualization and quantification: part 1. Evolution of the concept and dynamic records for smile capture. *American Journal of Orthodontics and Dentofacial Orthopedics* 124: 4–12
- Sarver D M, Ackerman M B 2003b Dynamic smile visualization and quantification: part 2. Smile analysis and treatment strategies. *American Journal of Orthodontics and Dentofacial Orthopedics* 124: 116–127
- Spahl T J, Witzig J W 1987 The clinical management of basic maxillofacial orthopedic appliances. PSG Publishing Co, Littleton
- Tjan A H, Miller G D, The J G 1984 Some esthetic factors in a smile. *Journal of Prosthetic Dentistry* 51: 24–28
- Wylie W L 1955 The mandibular incisor—its role in facial esthetics. *Angle Orthodontist* 25: 32–41
- Yang I-H, Nahm D-S, Baek S-H 2008 Which hard and soft tissue factors relate with the amount of buccal corridor space during smiling. *Angle Orthodontist* 78: 5–11
- Yoon M E, Jin T H, Dong J K 1992 A study on the smile in Korean youth. *Journal of Korean Academy of Prosthodontics* 30: 259–270
- Zachrisson B U 1998 Esthetic factors involved in anterior tooth display and the smile: vertical dimension. *Journal of Clinical Orthodontics* 32: 432–445
- Zachrisson B U 2007 Facial esthetics: guide to tooth positioning and maxillary incisor display. *World Journal of Orthodontics* 8: 308–314